

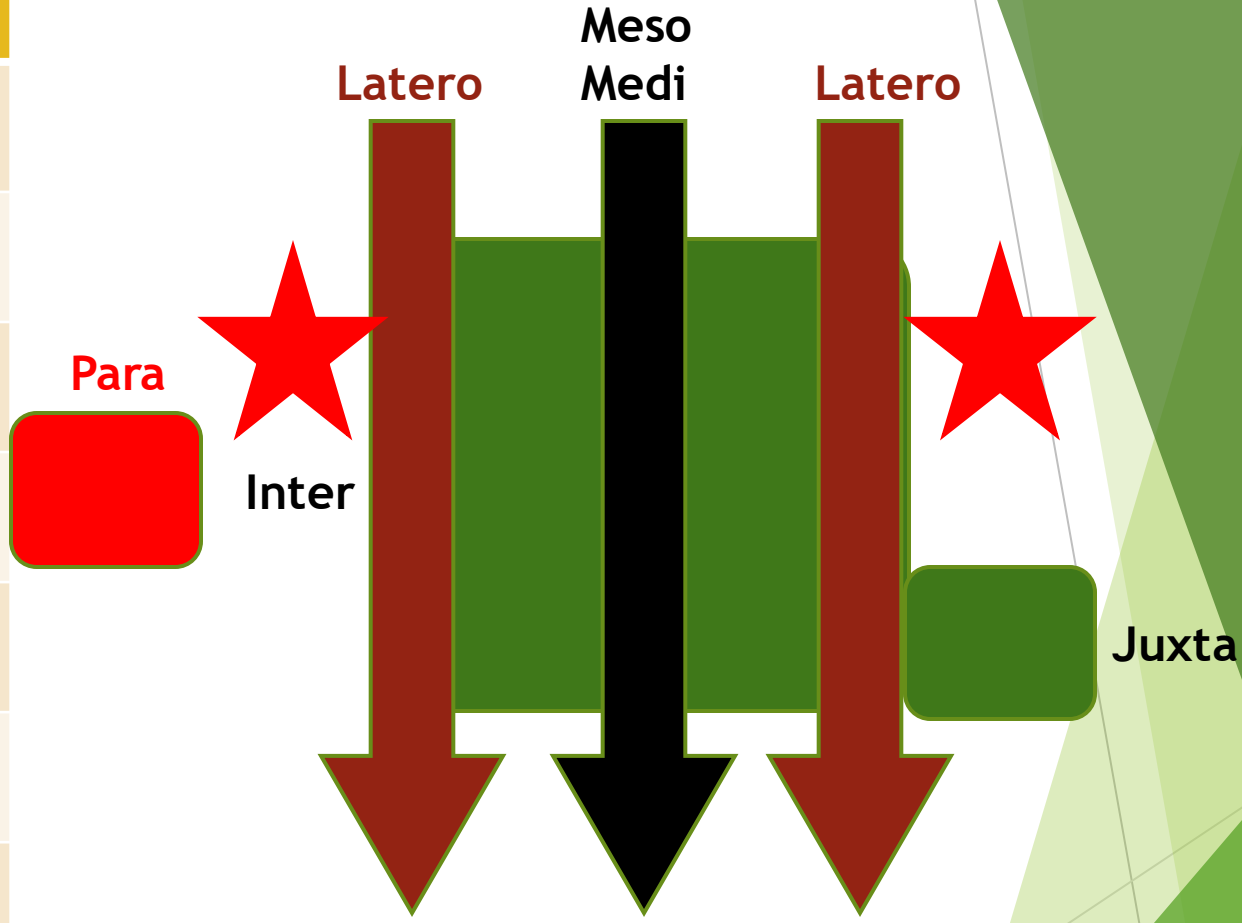
# Medical Terminology

## The Basics

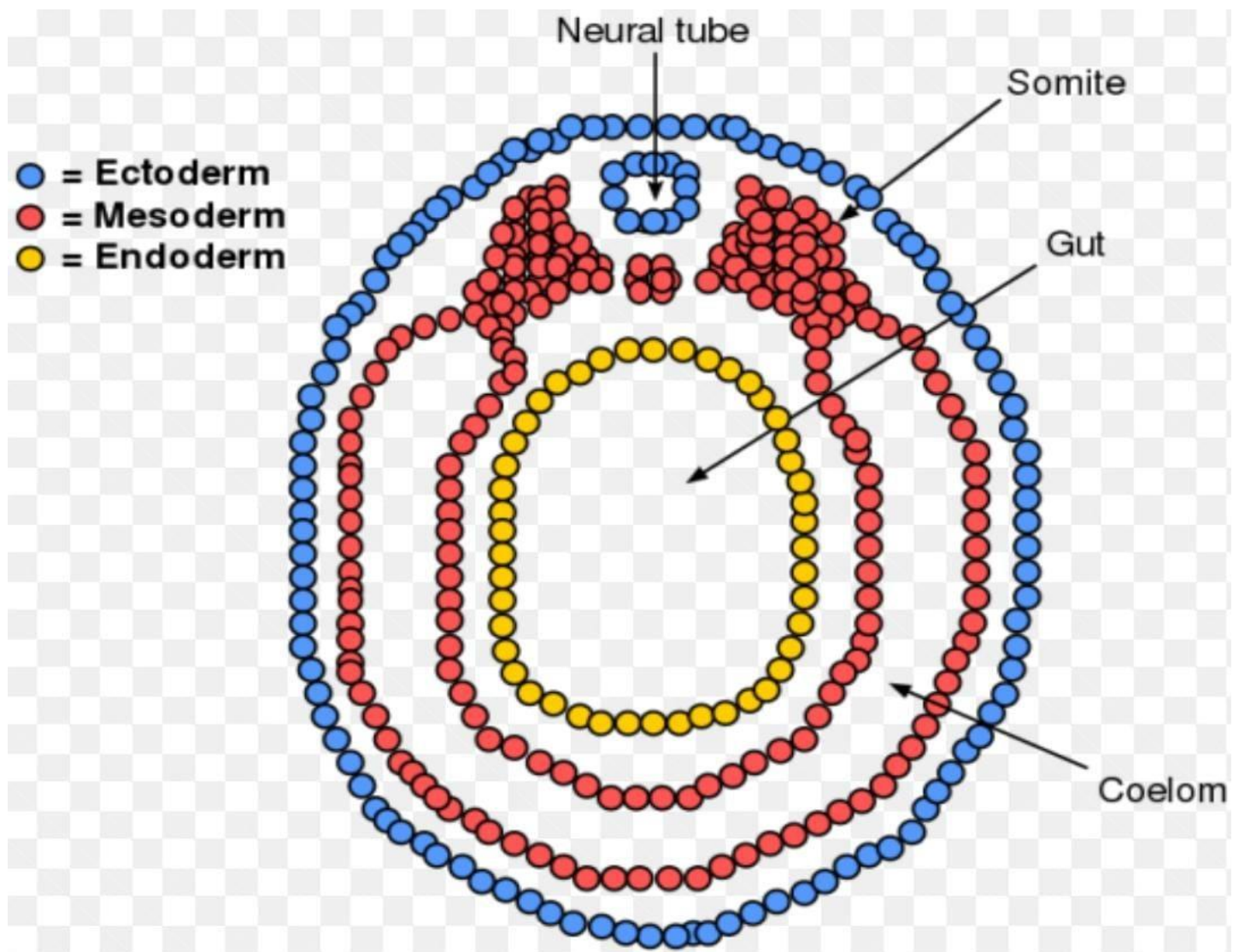
### 3<sup>rd</sup> Lecture

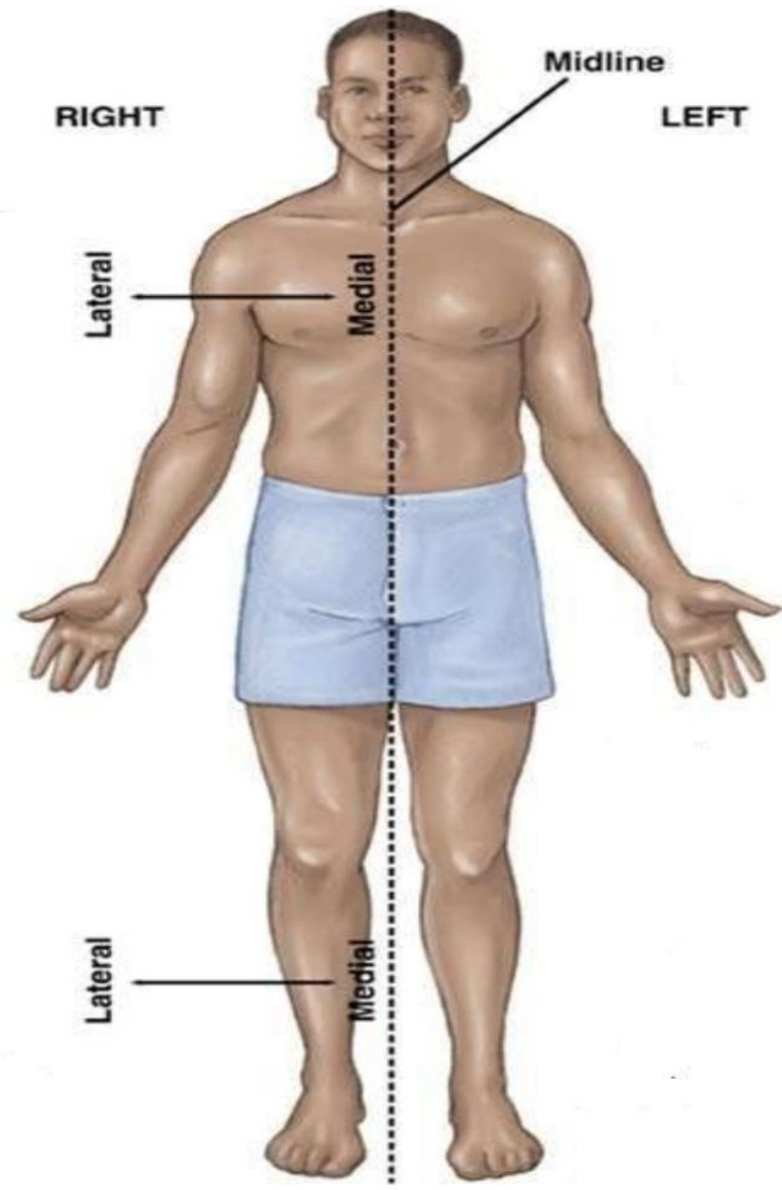
Assist. Lect. Noor Aziz

Meso-	Middle
Media(o/a)-	Middle
Latero-	Lateral
Para-	Nearby
Juxta-	Next to
Inter-	Between
Ambi-/Amphi	Both
Ipsi-	Same
Contra-	Against



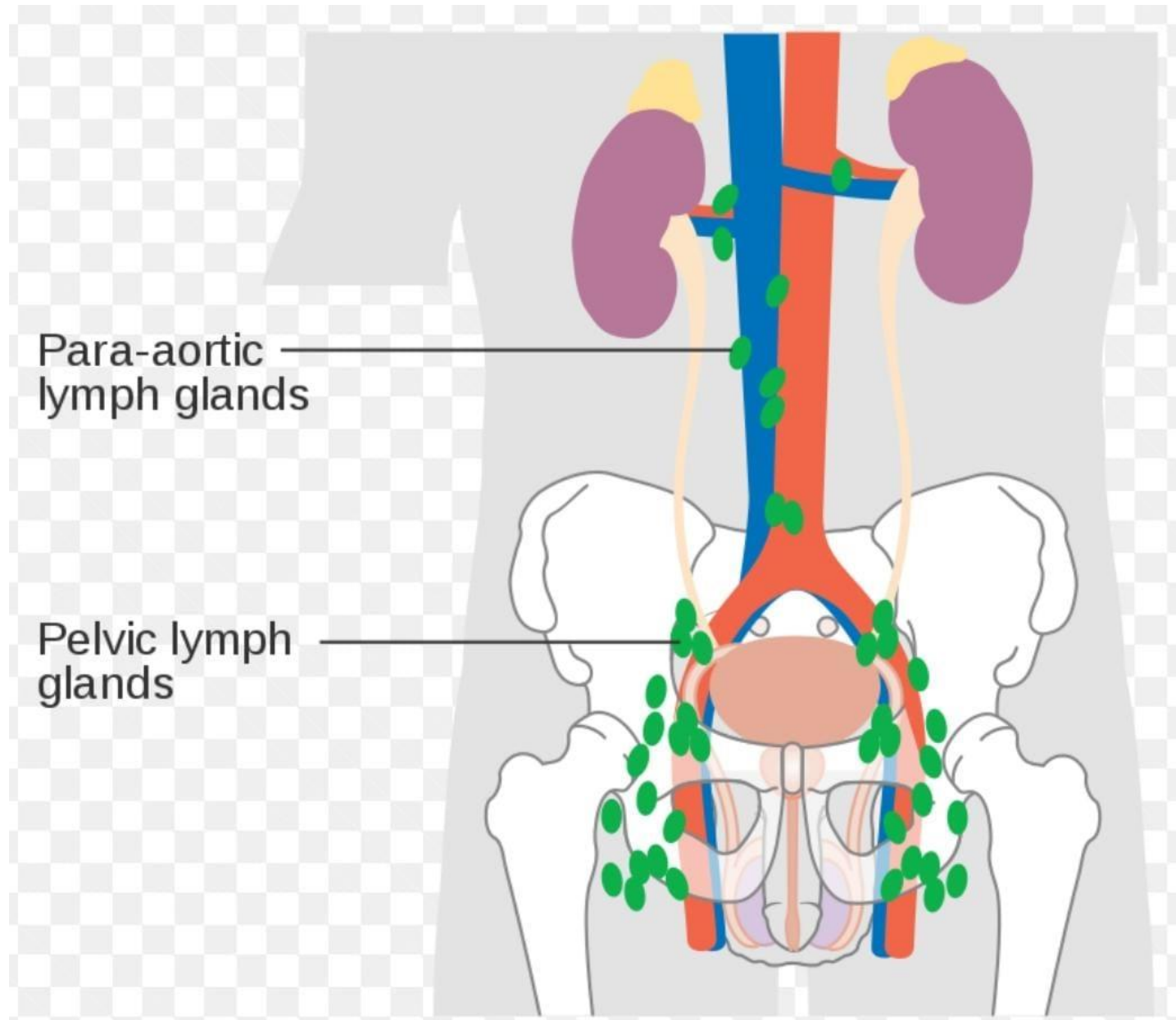
**Ambidextrous=Both** Hands  
**Amphibian=Both** Water and Land



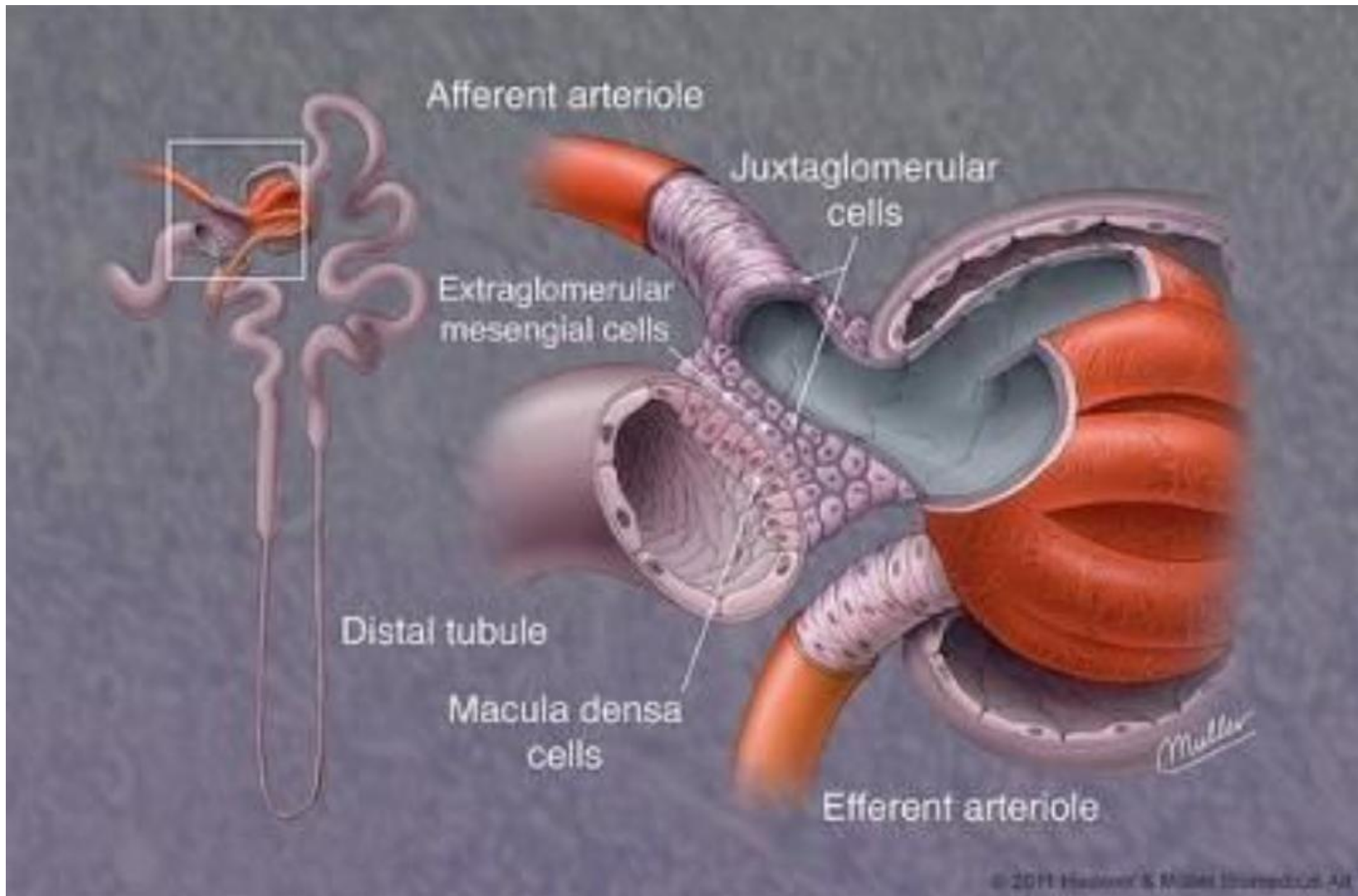


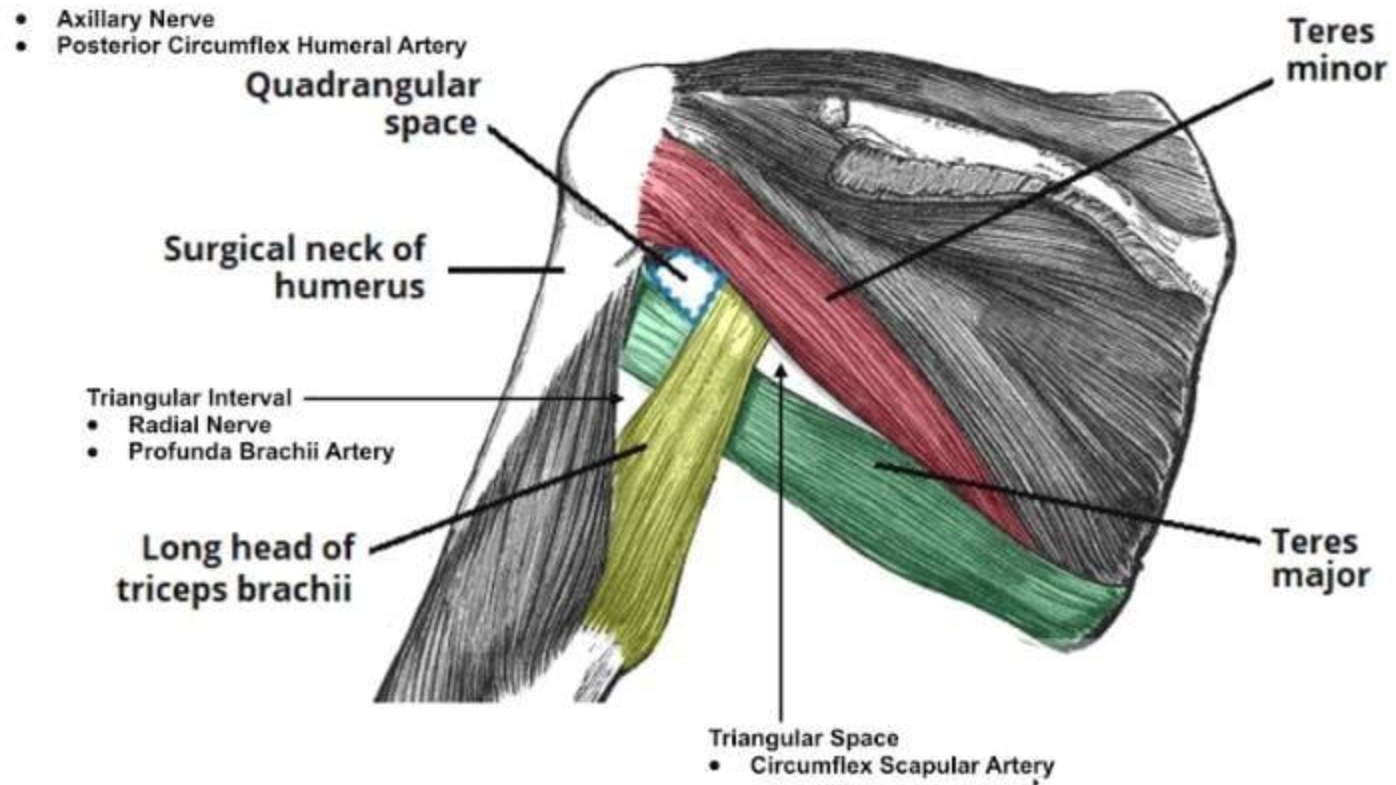
Para-aortic lymph glands

Pelvic lymph glands

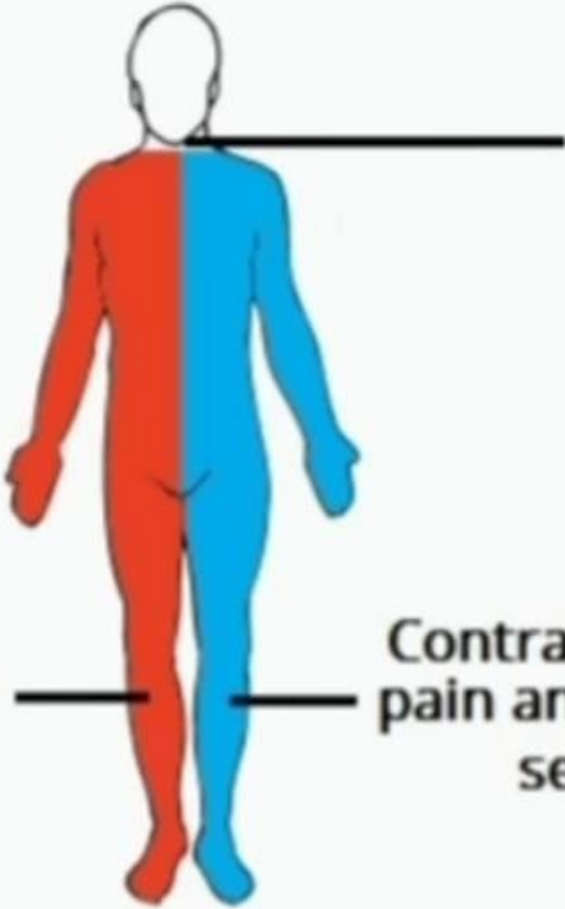
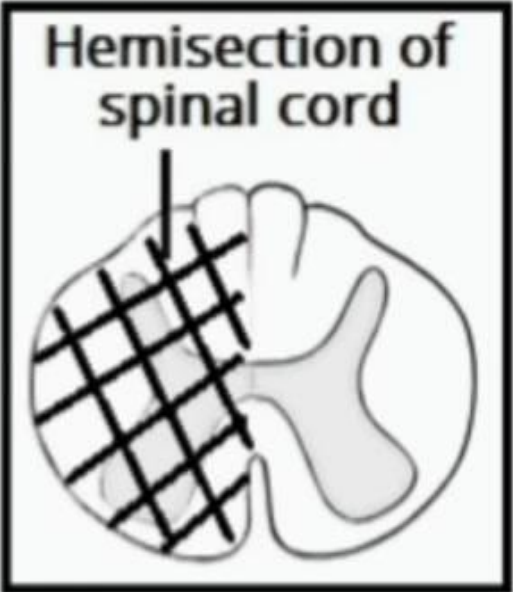








## Inter-muscular-spaces

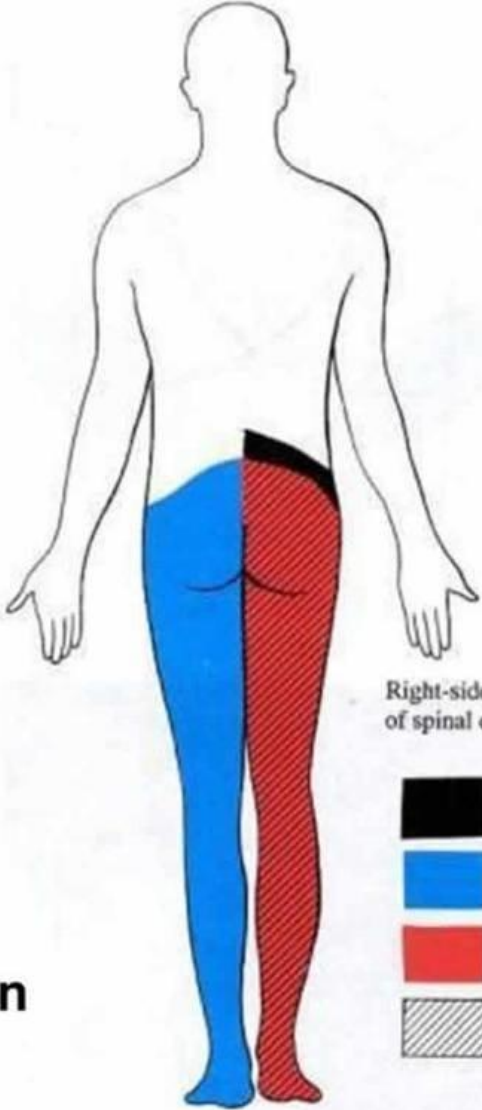
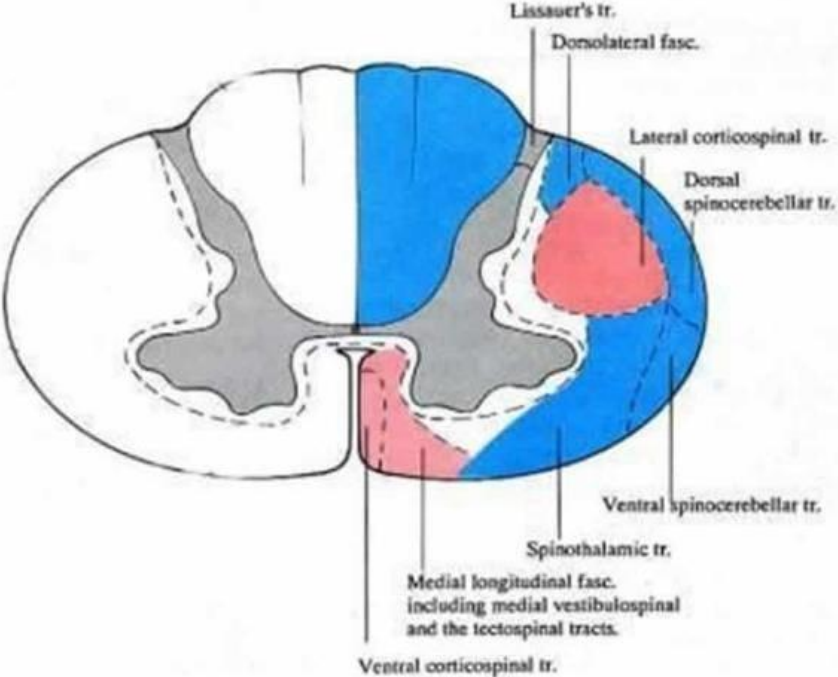


Ipsilateral loss of tactile sensation and proprioception

Contralateral loss of pain and temperature sensation



# Brown-Sequard Syndrome



Right-sided hemisection of spinal cord at T<sub>12</sub>

- Loss of all sensation
- Loss of pain and temperature
- Paralysis
- Loss of proprioception and vibration

**Right-sided Hemisection of spinal cord at T<sub>12</sub>.**

## Medical Roots

Abdomino-	Abdomen
Arterio-	Artery
Brachio-	Arm
Bronch-	Bronchus
Carcino-	Cancer
Cardio-	Heart
Colo-	Colon
Cyto-	Cell
Derm-/Dermato-	Skin
Encephalo-	Brain

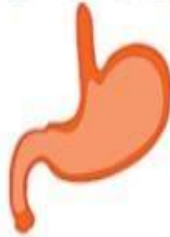Abdominal Muscles      Arteriosclerosis

Brachial Pulse      Bronchitis      Carcinogen

Cardiovascular      Colonoscopy      Cytotoxic

Dermatologist = Skin Practitioner      Encephalitis

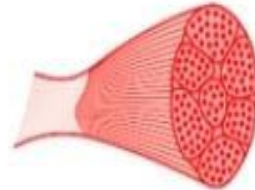
<b>Gastro-</b>	<b>Stomach</b>
<b>Intestino-</b>	<b>Intestine</b>
<b>Myo-</b>	<b>Muscle</b>
<b>Neuro-</b>	<b>Nerve</b>
<b>Oculo- /Ophthalmo-</b>	<b>Eye</b>
<b>Oto-</b>	<b>Ear</b>
<b>Pulmo-</b>	<b>Lungs</b>
<b>Thoraco-</b>	<b>Chest/Thorax</b>
<b>Thyro-</b>	<b>Thyroid Gland</b>
<b>Viscero-</b>	<b>Viscera(Internal Organs)</b>



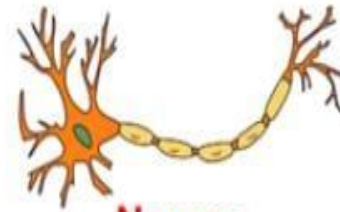
**Gastritis**



**Intestinal Obstruction**



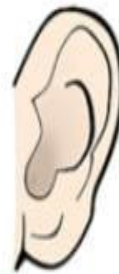**Myocardium**



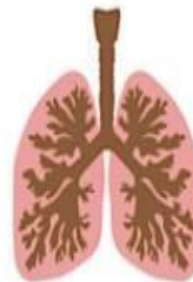**Neuron**



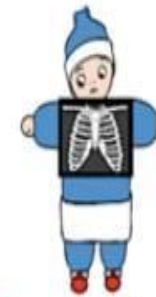**Oculomotor**




**Otoscope**



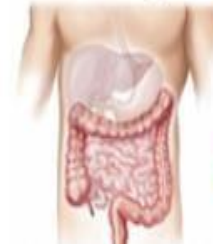**Pulmonologist**



**Thoracotomy**

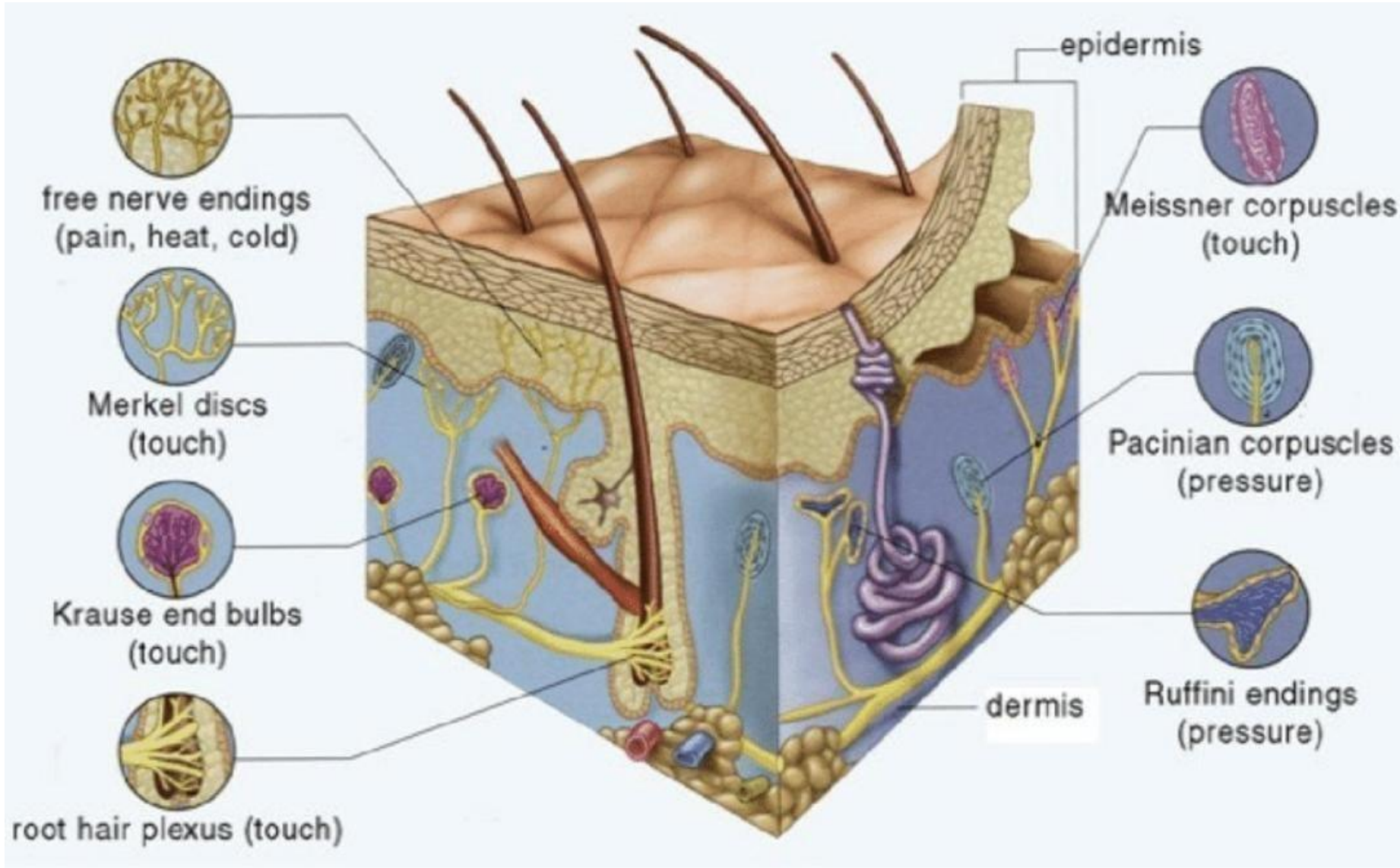


**Thyrotoxicosis**

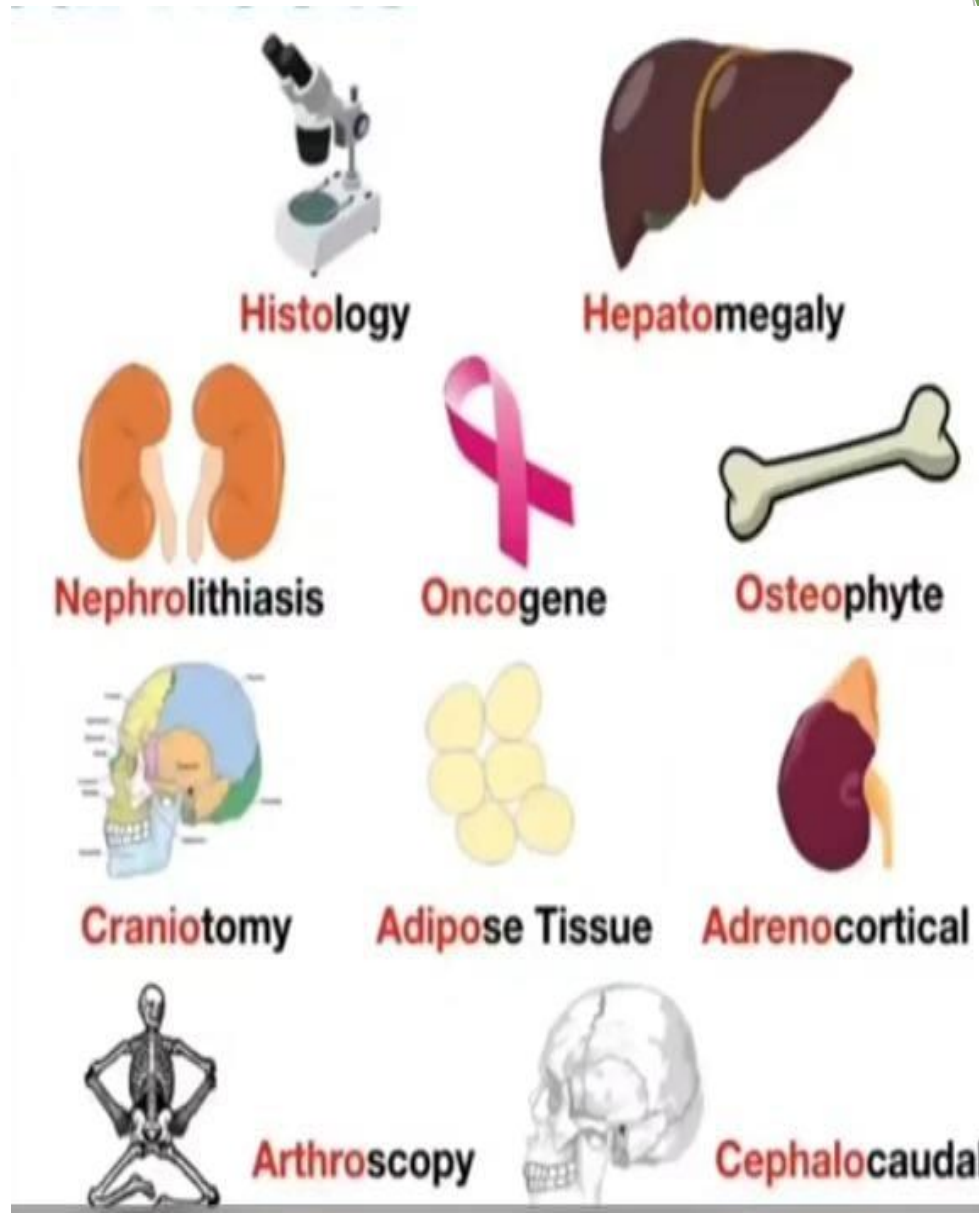


**Visceroceptors**





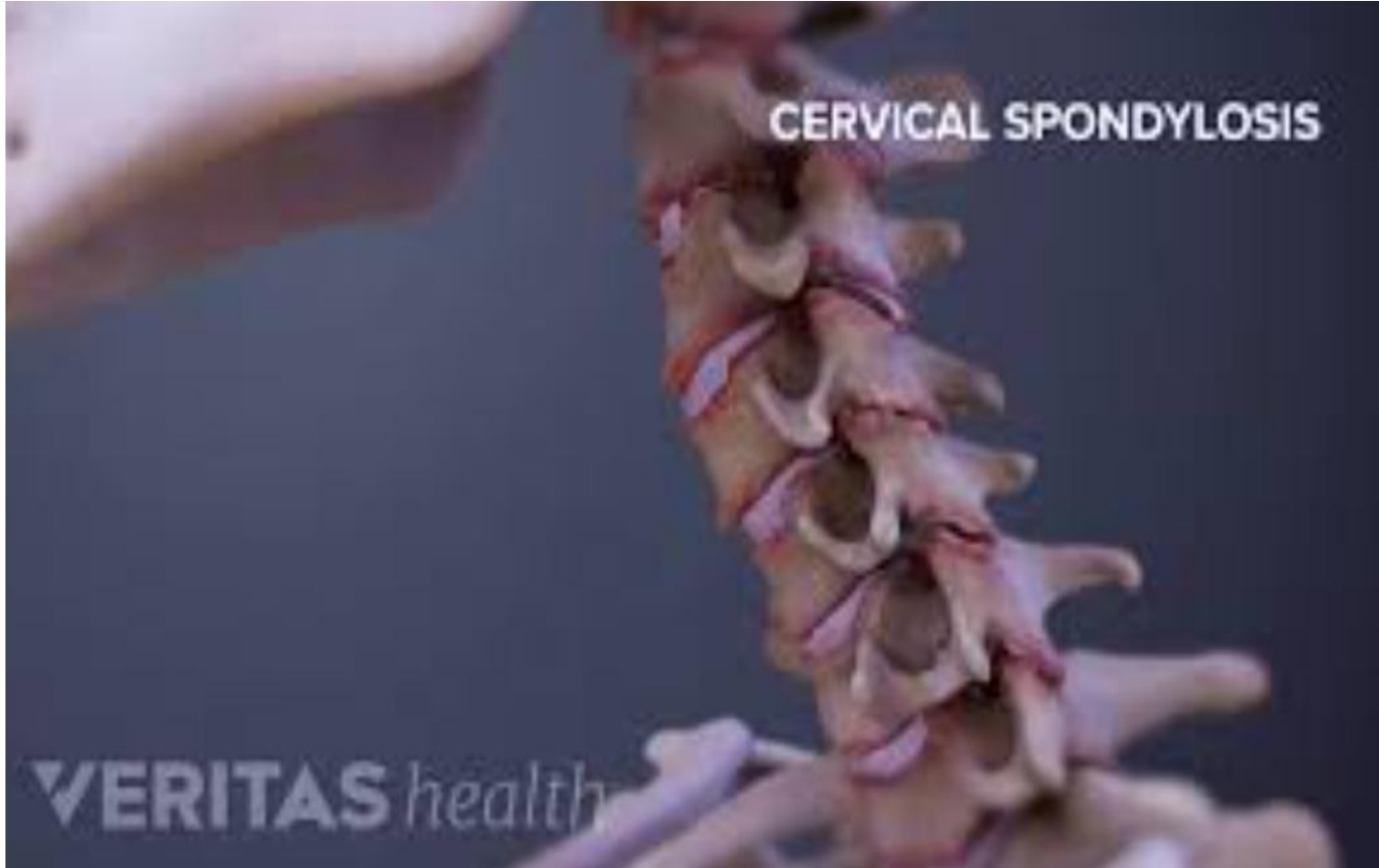Histo-/Histio-	Tissue
Hepato-	Liver
Nephro-	Kidney
Onco-	Tumor/Mass
Osteo-	Bone
Cranio-	Skull
Adipo-	Fat, Fatty, Tissue
Adreno-	Adrenal Gland
Arthro/Articulo-	Joint
Cephalo-	Head










## CERVICAL SPONDYLOSIS




VERITAS *health*

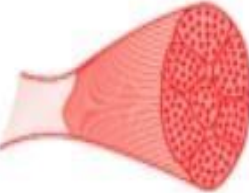



<b>Pneumo-</b>	<b>Lungs</b>
<b>Cerebello-</b>	<b>Cerebellum</b>
<b>Cerebro-</b>	<b>Cerebrum</b>
<b>Cysto-</b>	<b>Urinary Bladder</b>
<b>Duodeno-</b>	<b>Duodenum</b>
<b>Glosso-</b>	<b>Tongue</b>
<b>Laryngo-</b>	<b>Larynx</b>
<b>Lympho-</b>	<b>Lymph</b>
<b>Musculo-</b>	<b>Muscle</b>
<b>Naso-</b>	<b>Nose</b>

 **Pneumonia**
 **Cerebellopontine**

 **Cerebrovascular**
 **Cystoscopy**
 **Duodenography**

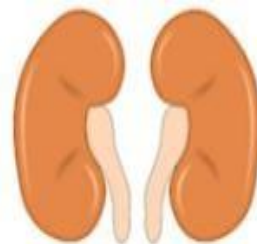 **Macroglossia**
 **Laryngospasm**
 **Lymphadenopathy**

 **Musculoskeletal**
 **Nasopharynx**

<b>Axillo-</b>	<b>Armpit</b>
<b>Reno-</b>	<b>Kidney</b>
<b>Rhino-</b>	<b>Nose</b>
<b>Sigmoido-</b>	<b>Sigmoid Colen</b>
<b>Sinus-</b>	<b>Sinuses</b>
<b>Tracheo-</b>	<b>Trachea</b>
<b>Tympano-</b>	<b>Eardum</b>
<b>Umbilico-</b>	<b>Umbilicus</b>
<b>Vasculo-</b>	<b>Blood Vessel</b>
<b>Vesico-</b>	<b>Bladder/Blister</b>



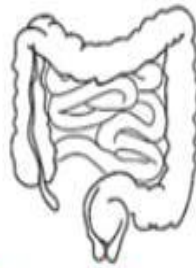**Axillary Vein**



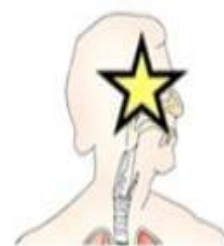**Renogram**



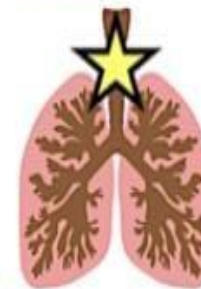**Rhinorrhea**



**Sigmoidoscopy**



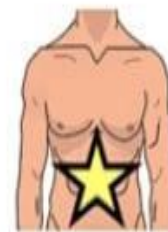**Sinusitis**



**Tracheostomy**



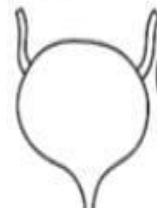**Tympanosclerosis**



**Umbilical Cord**



**Perivascular**

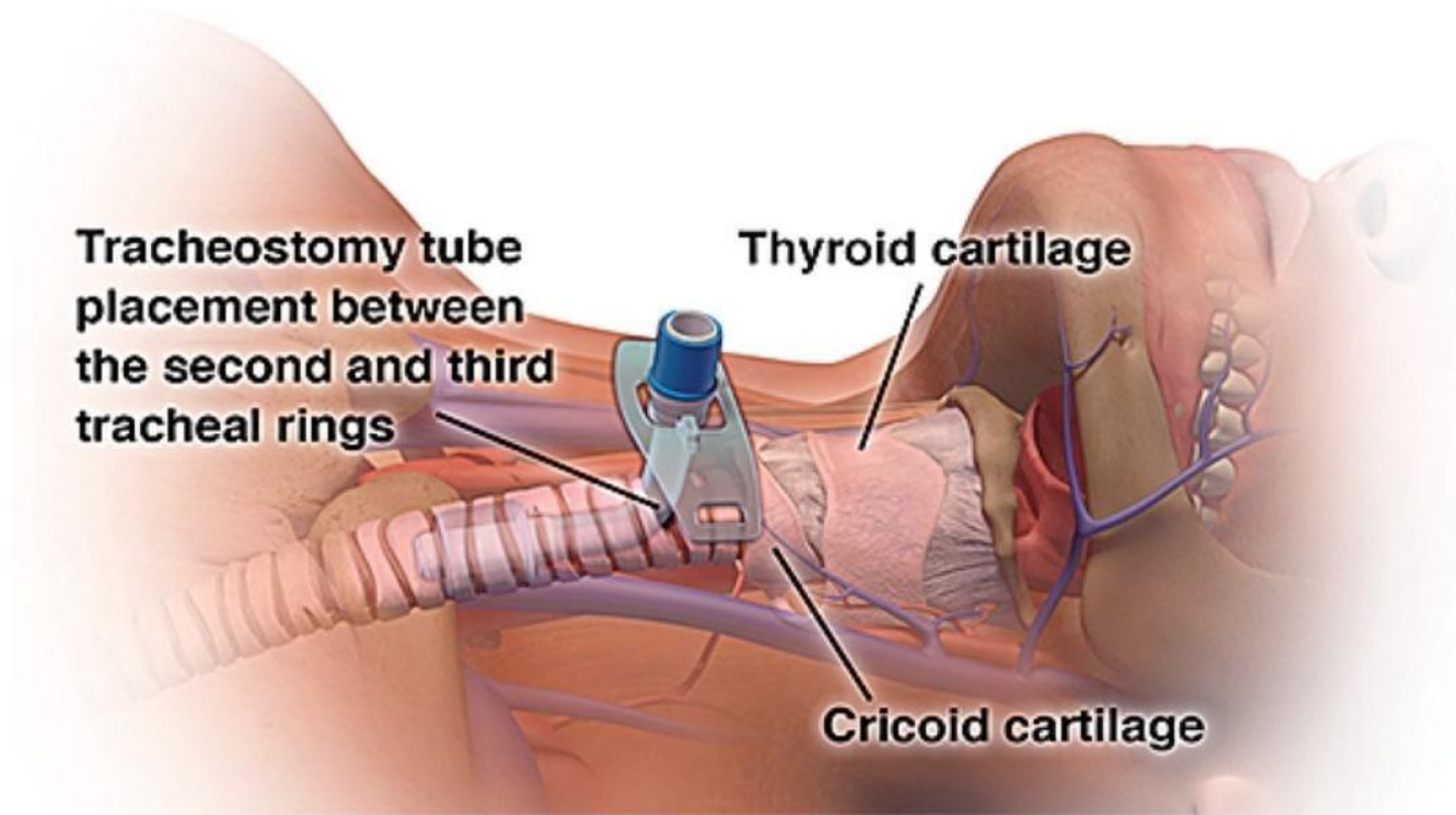


**Colovesical Fistula**

**Tracheostomy tube placement between the second and third tracheal rings**

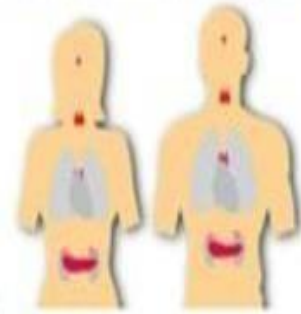
**Thyroid cartilage**

**Cricoid cartilage**

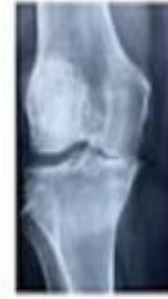



Adeno-	Gland
Chondro-	Cartilage
Blepharo-	Eyelid
Bucco-	Cheek
Carpo-	Wrist
Cholecysto-	Gallbladder
Costo-	Ribs
Cutaneo-	Skin
Gingivo-	Gums
Labio-	Lip



Adenocarcinoma



Chondroblast



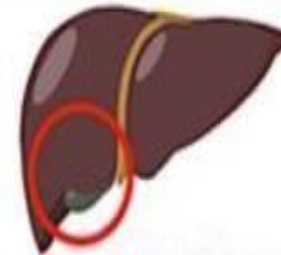Blepharospasm



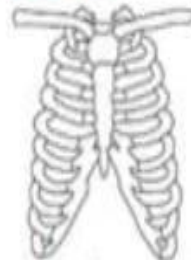
Buccinator



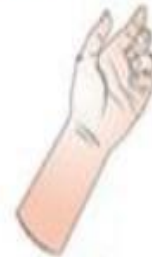Carpal/Metacarpal



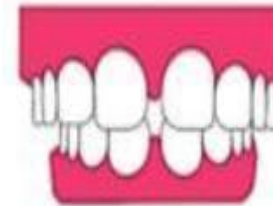Cholecystitis



Costochondritis



Transcutaneous



Supragingival



Labiodental